



## The post-op chest

Chest wall

---

---

---

---

---

---

### What will I gain from this video?

At the end of the video, you will know how to recognize the radiological features related to chest wall surgery.

---

---

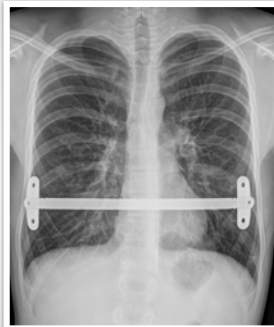
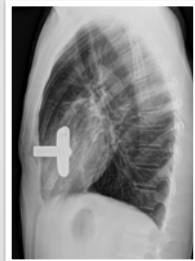---

---

---

---

### Pectus surgery



---

---

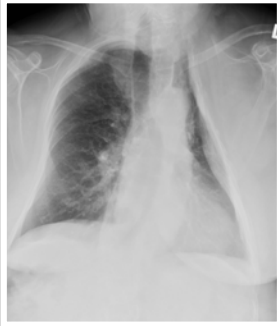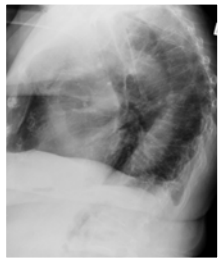
---

---

---

---

**Thoracoplasty**



---

---

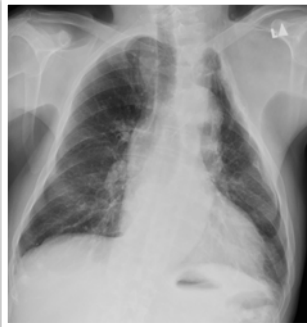
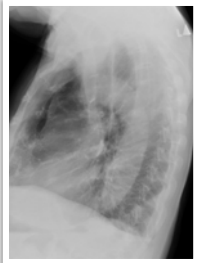---

---

---

---

**Thoracoplasty**



---

---

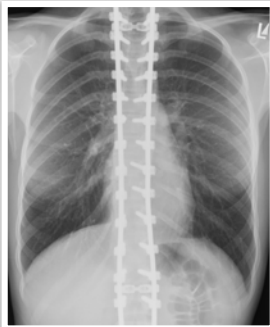
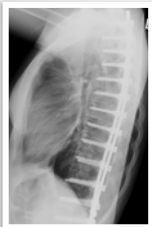---

---

---

---

**Harrington rod placement**



---

---

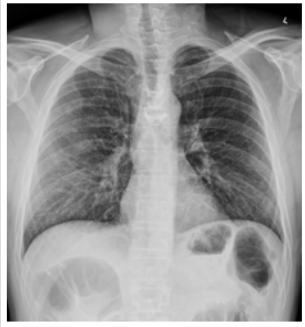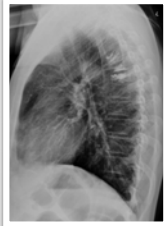
---

---

---

---

**Kyphoplasty/  
vertebroplasty**



---

---

---

---

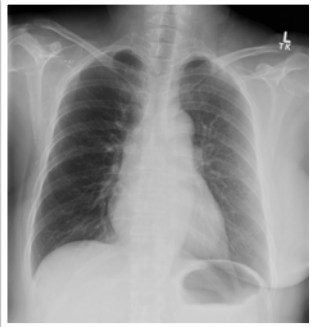
---

---

---

---

**Mastectomy**



---

---

---

---

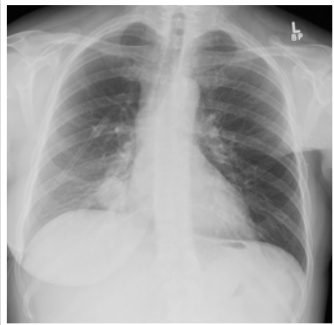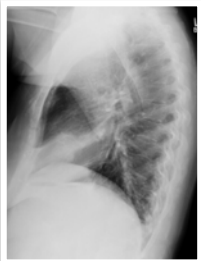---

---

---

---

**Mastectomy**



---

---

---

---

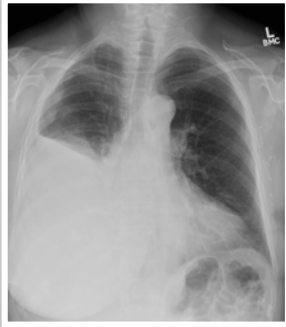---

---

---

---

**Mastectomy**



---

---

---

---

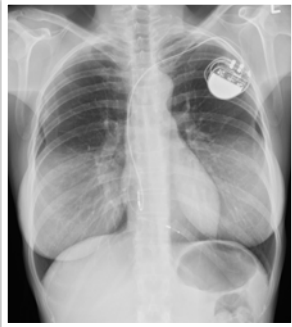
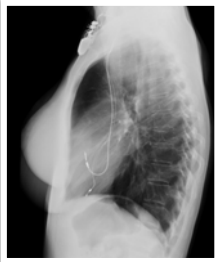---

---

---

---

**Breast implants**



---

---

---

---

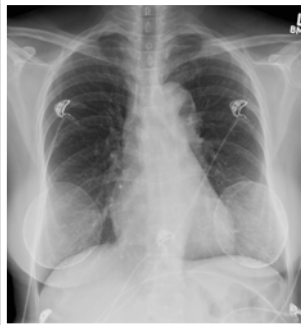
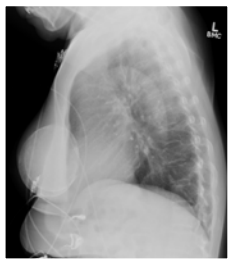---

---

---

---

**Breast implants**



---

---

---

---

---

---

---

---

Always compare to previous X-rays to identify complications.

Understand what type of surgery was performed.

Appearance will depend on type of surgery.

Early and late postoperative complications can occur.

---

---

---

---

---

